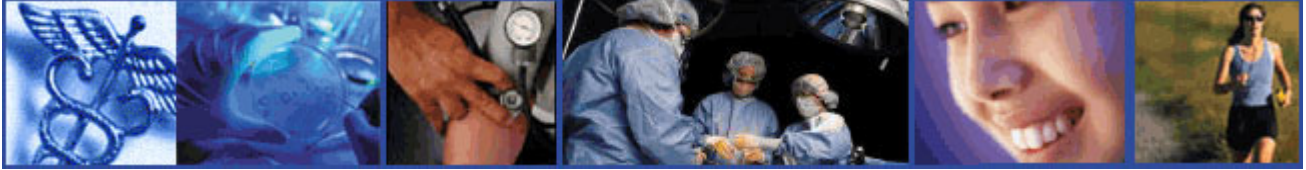

HeartFacts

**SOUTHERN CALIFORNIA
CARDIOVASCULAR CONSULTANTS**



visit us at www.socalcardiology.com

Complex Coronary Intervention- Getting it Right II

In the last issue of this newsletter, I set out to describe our approach to lesion severity in complex coronary intervention. I proposed a simplified assessment based on counting up the number of "Cs" that characterized a given lesion. That article dealt with calcium, clot and cracks (erosion or disruption). More trouble lies ahead with Curves, bifurCations, ostial loCation and Chronic total occlusions.

The coronary arteries are so named because they reminded the early anatomists of the curved metal pieces on the velvet and gold English crown. (L. corona= crown). Unlike a number of peripheral arteries the coronary arteries curve inward to accommodate the shape of the heart. Moreover, if the patient is a long-standing hypertensive there may

be tortuous curves created by the disease process. These curves are identical to the tortuosity seen in retinal arteries on the funduscopic exam of many hypertensive patients.

Plaques located on curves are a special challenge. Inflation of a balloon tends to straighten the segment and in so doing produce dissection. This may be avoided or minimized by selecting a balloon that is longer than the plaque being approached. Long balloons tend to conform to the curvature of the vessel. The "heel" and "toe" of a long balloon anchor along the continuation of the curve and maintain some curvature of the central portion of the balloon. Dissection is minimized and if it occurs tends to be limited by the heel and toe preventing distal and proximal propagation.

A dissection on curves is best dealt with by deploying a stent with good lateral flexion as one of its inherent properties. Deploying a rigid stent on a curve produces hinge points at the outlet and inlet of the device that may traumatize the vessel with each systole. This may explain the propensity for

edge restenosis seen with some stent designs. If the plaque located on a curve is calcified, rotational atherectomy is a tidy way of modifying the plaque before deploying a flexible stent. Rotablator rarely produces a dissection when used properly.

Bifurcation lesions are yet another challenge. These lesions start in the main branch and continue into the divisional branches. A number of techniques have been devised for dealing with these very tough cases. The first of these was to deploy separate guidewires into each branch -- and dilate first one branch then the other. This technique tended to shift plaque back and forth at the "carina" jeopardizing first one lumen then the other. This experience led to the concept of "kissing balloons" -- inflating side-by-side balloons in the main artery, each balloon continuing into the branch vessel. This tended to pinch the carinal plaque and compress it. The ostium of each branch was thus preserved. Restenosis rates were unfortunately high at about 50 percent.

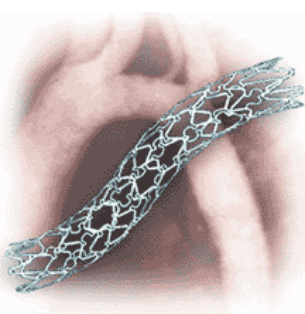
TABLE I

Simplified Assessment of Lesion Severity:

- C**alcium
- C**lot
- C**racks
- C**urves
- B**ifurcations
- O**stial loCations
- C**hronic total occlusion

Interventionalists then turned to various configurations of two stents. Side-by-side stents, T-stents, and the infamous stent crush were all tried. These are as difficult to describe as they are to perform. Suffice it to say, each technique has had its champion whose bravado was as short-lived as his initial enthusiasm was long.

At present the best technique appears to be deployment of a single stent starting in the main vessel and continuing into the larger of the divisional branches. The guide wire is then pulled back and used to seek the ostium of the minor branch through the stent struts. A balloon catheter is advanced over the guide wire and



Complex Coronary Intervention (continued)

TABLE 2

Lesion Classification:

This is the classification of the American Heart Association/American College of Cardiology Task Force:

Type "A" Lesions:

Discrete (10mm. Length)
 Concentric
 Readily Accessible
 Non-angulated segment, <45 degrees
 Smooth contour
 Little or no calcification
 Less than totally occlusive
 Not ostial in location
 No major branch involvement
 Absence of thrombosis

Type "B" Lesions:

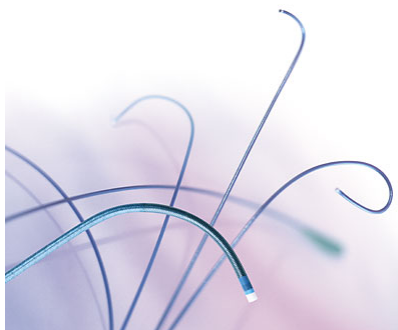
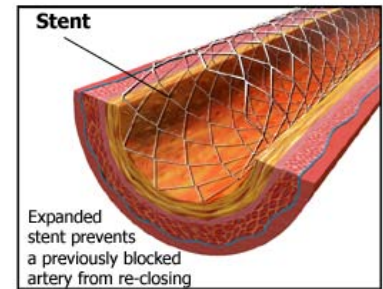
Tubular (10 to 20 mm length)
 Eccentric
 Moder. tortuosity of proximal segment
 Moderate angulated segment, 45-90 °
 Irregular contour
 Moderate to heavy calcification
 Total occlusion > 3 months old
 Ostial in location
 Bifurcation lesions requiring double guidewires
 Some thrombus present

Type "C" Lesions:

Diffuse (> 2 cm length)
 Excessive tortuosity of proximal segment
 Extremely angulated segment, > 90 °
 Total occlusion > 3 months old
 Inability to protect major side branches
 Degenerated vein grafts with friable lesions

inflated, thereby pushing the metal struts aside so the ostium is clear. This approach has cut the restenosis rate for bifurcation stenting in half. Employing a drug eluting stent may lower the rate even further although this has not been validated in a clinical trial.

Lesions at the ostium of any of the coronary vessels or their branches pose a special challenge: how to stent without leaving stent hanging out in the aorta or main coronary artery. One must choose a stent with good radio-opacity so it can be seen. It must also have superb radial strength since the ostium has a collar of muscle that tends to cause vigorous recoil. Lining up the stent with the ostium by taking multiple "cine runs" from different views will usually allow the operator to "nail" the deployment. Occasionally the stent delivery system will jump forward as the stent balloon is being inflated and the ostium is missed. In this case the stent winds up being deployed slightly downstream. A second stent is deployed within the first stent in order to leave "metal" covering the ostium.



"Long balloons tend to conform to the curvature of the vessel."

In a future newsletter I will discuss the **bete noire** of coronary intervention -- chronic total occlusions. •

L.R. O'Connor, M.D., F.A.C.C.



Lawrence R. O'Connor, M.D.



Y. Joseph Wen, M.D.